

AN UNUSUAL ETIOLOGICAL AGENT IN PAROTID ABSCESS FOLLOWING BLUNT TRAUMA: KOCURIA KRISTINAE

Head and Neck Surgery

Submitted : 30.06.2025

Accepted : 23.09.2025

Published : 23.09.2025

Vural Akın¹, Hasan Yasan², Çağlar Irmak³, İhsan Kulaksız⁴¹ Süleyman Demirel Üniversitesi Tıp Fakültesi² Süleyman Demirel Üniversitesi Tıp Fakültesi Kulak Burun Boğaz Hastalıkları Ana Bilim Dalı³ İzmir Tepecik Eğitim ve Araştırma Hastanesi Enfeksiyon Hastalıkları ve Klinik Mikrobiyoloji Ana Bilim Dalı⁴ Yüksekova Devlet Hastanesi Tıbbi Mikrobiyoloji Kliniği

Özet

KÜNT TRAVMA SONRASI GELİŞEN PAROTİS APSESİNDE SIRA DIŞI BİR ETKEN: KOCURIA KRISTINAE

Parotis bezi patolojileri, fasiyal sinirin potansiyel tutulumu nedeniyle klinik olarak önemlidir. Fasiyal sinir, enfeksiyöz patolojiler, travma, tümörler ve iatrojenik patolojilerden etkilenebilir. Sıklıkla kötü ağız hijyeni, immünsüpresyon, dehidratasyon ve sialolithiasis gibi durumların varlığında gelişen parotis apseleri, dikkatli bir yönetim gerektirir. Bu makalede, künt travmaya sekonder parotis apsesi gelişen 30 yaşında immünokompetan bir erkek hasta sunulmaktadır. Bu vaka, hem künt travmayı takiben gelişmesi hem de kültürde Kocuria kristinae'nin izole edilmesi nedeniyle literatürdeki ilk olgudur.

Anahtar kelimeler: Travma, Künt Travma, Parotis Absesi, Kocuria kristinae

Abstract

AN UNUSUAL ETIOLOGICAL AGENT IN PAROTID ABSCESS FOLLOWING BLUNT TRAUMA: KOCURIA KRISTINAE

Parotid gland pathologies are clinically significant due to potential involvement of the facial nerve. The facial nerve may be affected by infectious pathologies, trauma, tumors, and iatrogenic causes. Parotid abscesses, which frequently develop in the presence of conditions such as poor oral hygiene, immunosuppression, dehydration, and sialolithiasis, require careful management for this reason. This article presents the case of a 30-year-old immunocompetent male patient with a parotid abscess secondary to blunt trauma. This case is unique in the literature both due to its development following blunt trauma and the isolation of Kocuria kristinae in culture.

Keywords: Trauma, Blunt Trauma, Parotid Abscess, Kocuria kristinae

Introduction

The parotid gland may be injured either bluntly or by penetration in head and neck trauma. Traumatic parotid pathologies account for 2.5% of all parotid pathologies [1,2]. In injuries occurring at the gland level, the parenchyma is affected, whereas injuries involving the anterior aspect of the gland may involve the Stensen's duct. The risk of facial nerve involvement in parotid gland injuries makes these pathologies particularly significant [1].

Parotid abscess (PA) typically develops following acute purulent sialadenitis. Reported risk factors for PA include poor oral hygiene, immunosuppression, sialolithiasis, and dehydration. Due to its anatomical relationship with the facial nerve, PA presents a therapeutic challenge [3]. The primary treatment strategy consists of drainage and appropriate antibiotic therapy [3-5]. While the most frequently reported pathogens in PA are Staphylococcus spp., anaerobic bacteria, and Streptococcus spp., numerous other pathogens have also been isolated in PA cases [3,4]. The differential diagnosis of PA also includes sialadenitis, sialolithiasis, soft tissue infections of dental origin, and

temporomandibular joint disorders [3-6].

Kocuria kristinae is an aerobic, gram-positive, catalase-positive, coagulase-negative, and non-hemolytic coccus that is part of the skin and oral flora [7-11]. *Kocuria kristinae* is generally considered to become pathogenic in immunosuppressed patients [7-9,11]. The most common infections associated with *Kocuria* spp. include bacteremia, skin and soft tissue infections, endophthalmitis, infectious endocarditis, and peritonitis. Recently, an increasing number of *Kocuria* spp. infections were reported in immunocompetent individuals [11].

In this case report, a patient with parotid abscess secondary to blunt trauma, in which *Kocuria kristinae* was identified as the causative pathogen, is presented in light of the literature. This is the first reported case in the literature both in terms of its development secondary to blunt trauma and the isolation of *Kocuria kristinae* in culture.

Case Report

A 30-year-old male patient with no known medical history was referred from the Emergency Department to the Otorhinolaryngology clinic due to painful swelling over the mandible. It was learned that five days prior, he had sustained a blunt trauma to the affected area while playing football. The patient reported experiencing pain immediately after the impact, with no mandibular fracture detected upon evaluation in the Emergency Department, and no open wound associated with the trauma. Over the past two days, he had developed swelling in the painful area, with increasing pain intensity. On physical examination, a lesion was observed at the level of the left mandibular angle, characterized by erythema and increased temperature of the overlying skin, as well as tenderness and fluctuance upon palpation (Figure 1).




Figure 1

Lesion at the left mandibular angle, causing erythema and increased temperature of the skin, tender, and exhibiting fluctuation.

Trismus was present, with restricted and painful mouth opening of approximately 2 cm. Serous saliva of normal consistency was observed flowing from the Stensen's duct orifice. No additional significant findings were noted on

physical examination. Neck ultrasonography revealed a dense fluid collection of approximately 3×2 cm within the left parotid gland, suggestive of an abscess. To further evaluate potential post-traumatic fractures, the extent of abscess spread, its origin, and involvement of cervical spaces, contrast-enhanced neck computed tomography (CT) was performed. A well-defined collection measuring approximately 3 cm in diameter, consistent with an isolated abscess within the left parotid gland, was observed (Figure 2).

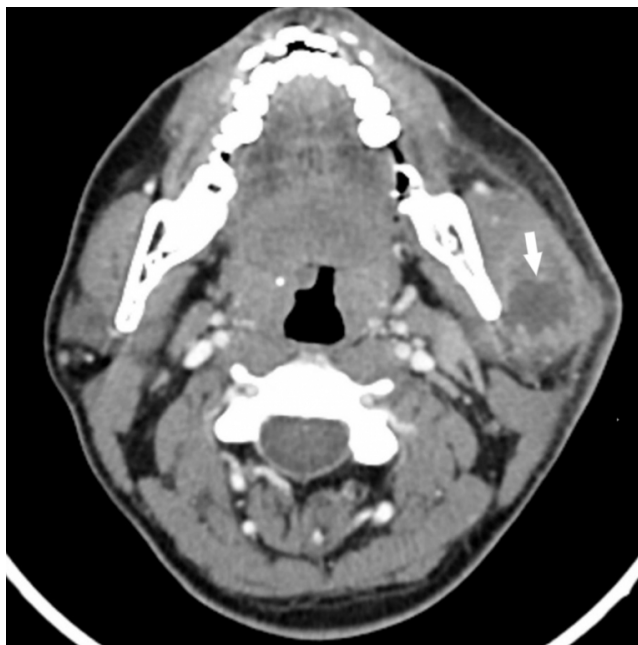

Figure 2A

Contrast-enhanced CT showing an abscess-like image within the left parotid parenchyma, white arrow, axial section.

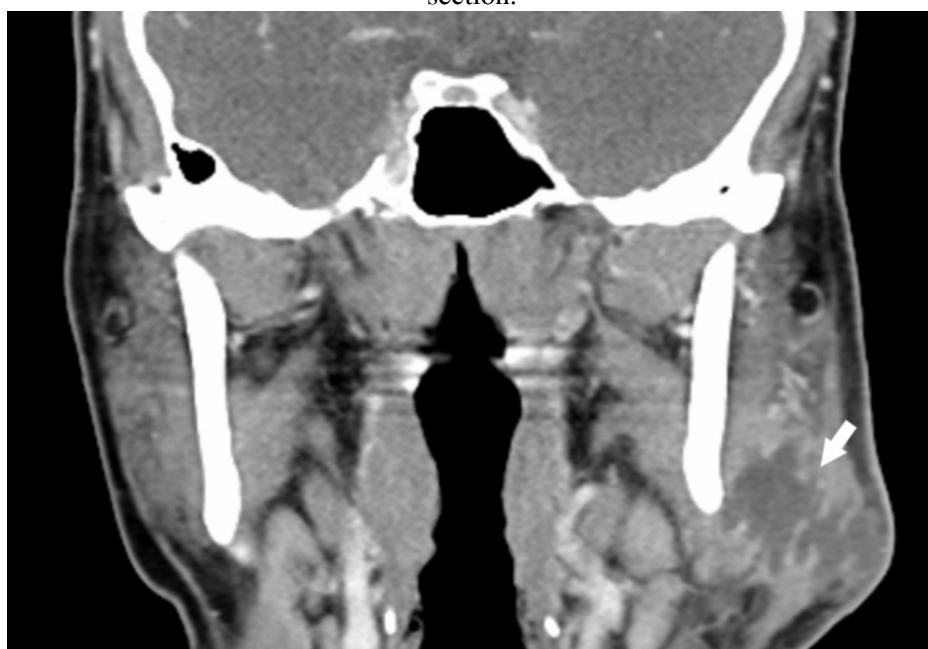

Figure 2B

Contrast-enhanced CT showing an abscess-like image within the left parotid parenchyma, white arrow, coronal section.

No additional findings were detected on radiological examination. The patient's blood test results are presented in Table 1.

Test	Day of Admission	3rd Day of Treatment	Follow-up Examination	Reference Range
Leukocytes ($10^3\mu\text{L}$)	6.93	5.33	8.89	3.5 – 9.5
Neutrophil ($10^3\mu\text{L}$)	5.43	3.17	5.69	1.8 – 6.3
Lymphocytes ($10^3\mu\text{L}$)	0.79	1.59	2.33	1.1 – 3.2
Monocytes($10^3\mu\text{L}$)	0.59	0.29	0.51	0.1 – 0.6
C-Reactive Protein (mg/L)	122.5	19.8	3.5	0- 5

Table 1

C-Reactive Protein and Complete Blood Count Results During Follow-Up

For possible dental etiology, the Endodontics Clinic was consulted for the patient. He reported no dental symptoms before or after the trauma. Based on history and dental examination, a dental pathology was not considered as the cause of the abscess. Abscess drainage was performed, yielding a thick, purulent fluid. Following drainage, trismus improved. The abscess sample was collected and sent to the microbiology laboratory. After drainage, based on the recommendation of the Infectious Diseases specialist, intravenous ampicillin-sulbactam (4×1.5 g) was initiated. On the third day of treatment, significant clinical and laboratory response was observed, and based on the recommendation of the Infectious Diseases specialist, the patient was discharged with oral amoxicillin-clavulanate (2×1 g). Cultures from the parotid abscess were cultivated using sheep blood agar and eosin methylene blue agar plates. The plates were incubated at 37 °C for 48 hours. Tiny, smooth, shiny, and non-hemolytic colonies were observed on blood agar, whereas no growth was detected on eosin methylene blue agar. Gram staining of the colonies revealed gram-positive cocci. The organism was catalase-positive and coagulase-negative. Identification was performed using the Vitek 2 system (BioMérieux, France), and the isolate was identified as *Kocuria kristinae*. Antibiotic susceptibility testing was not performed due to the absence of defined breakpoints for *Kocuria kristinae* in the EUCAST guidelines [12]. At the follow-up examination on post-drainage day 10, the patient showed no signs of infection on physical examination, and C-reactive protein levels had returned to normal; therefore, antibiotic therapy was discontinued.

Informed consent was obtained from the patient for the publication of this case report.

Discussion

Although PA is considered to be more common in elderly and/or immunosuppressed patients, multiple studies demonstrated its occurrence in healthy individuals across all age groups [3-5]. On physical examination, a fluctuating swelling in the parotid region is the most critical finding suggestive of an abscess. CT or ultrasonography provides sufficient information for the diagnosis of an abscess. When complications are suspected, CT is the preferred imaging modality [4]. Reported complications include facial nerve paralysis, cervicofacial cellulitis, osteomyelitis, temporal lobe abscess, deep neck infections, necrotizing fasciitis, mediastinitis, airway obstruction, and septic shock. Prompt diagnosis and effective treatment are crucial to prevent these complications [3,4]. Abscess drainage can be performed via aspiration or incision [4]. Aspiration drainage is recommended as the initial approach due to its lower risk of facial nerve injury [5]. The recommended duration of antibiotic therapy is generally 10–14 days [3,4]. To date, there are no reported cases of PA secondary to blunt trauma in the literature. Possible etiological mechanisms in our case include the parenchyma becoming susceptible to infection due to the effects of extravasated saliva following trauma or secondary infection of an associated

hematoma.

Previously, *Kocuria* spp. was classified as *Micrococcus* or coagulase-negative *Staphylococcus* when bacterial typing was performed manually. However, more accurate identification has been achieved with the advances in automated systems [7]. The most commonly used method for identification is VITEK 2 [9,11]. Since this bacterium is generally regarded as a contaminant, its pathogenic potential has often been overlooked. However, in recent years, an increase in both superficial and deep tissue infections caused by *Kocuria* spp. was reported [7]. Due to phenotypic similarities between *Kocuria* spp. and coagulase-negative *Staphylococcus* spp., misidentifications between these genera have occurred. Currently, there are no established treatment guidelines for *Kocuria* infections, and empirical treatment is initiated in most cases. It was reported that *Kocuria* spp. is generally susceptible to amoxicillin-clavulanate [11].

In a study by Chaubey et al., infections caused by *Kocuria kristinae* were evaluated in patients undergoing treatment for head and neck malignancies. In this case series, male patients were predominant, which was attributed to the higher incidence of head and neck cancers in men. Similarly, the mean age was reported as 50.8 years, but this finding was not considered significant on its own. It was demonstrated that *Kocuria kristinae* infections occur in a wide age range, from neonates to elderly individuals. In the study by Chaubey et al., most patients exhibited leukocytosis and elevated CRP levels [7]. Amina et al. reported a case of meningitis secondary to sphenoid sinusitis in a pediatric patient without immunosuppression, in which *Kocuria kristinae* was identified as the causative agent. The pathogen was found to be susceptible to penicillin G, amoxicillin, cefotaxime, erythromycin, spiramycin, lincomycin, ofloxacin, pristinamycin, levofloxacin, teicoplanin, and vancomycin, while exhibiting low-level resistance to streptomycin, kanamycin, and gentamicin. The patient was successfully treated with a combination of cefotaxime and vancomycin [8]. Tsai et al. reported a case of a brain abscess caused by *Kocuria* spp. in a 52-year-old patient with diabetes mellitus. In this case, the pathogen was found to be susceptible to penicillin, cloxacillin, cefmetazole, clindamycin, meropenem, penicillin G, ampicillin/sulbactam, and piperacillin/tazobactam [9].

Conclusion

Early and effective treatment of PA is crucial for preventing complications. Accurate identification of the causative bacterium is essential for appropriate antibiotic therapy planning. With the introduction of advanced technological systems, bacterial classification has become more precise. This has led to the recognition of certain previously overlooked bacteria as causative agents in various infections. A similar situation applies to *Kocuria kristinae*.

Acknowledgement

None.

Informed Consent: Informed consent was obtained from the patient for the publication of this case report.

References

1. Akinbami BO. Traumatic diseases of parotid gland and sequelae. Review of literature and case reports. *Niger J Clin Pract.* 2009;12:212-5.
2. Medeiros Júnior R, et al. Giant sialoceles following facial trauma. *Braz Dent J.* 2012;23:82-6.

3. Mayer M, et al. Bi-institutional analysis of microbiological spectrum and therapeutic management of parotid abscesses. *Head Face Med.* 2024;20:38.
4. Srivanitchapoom C, Yata K. Clinical characteristics that predict parotid abscess: An observational cohort study. *Ann Med Surg (Lond).* 2021;64:102230.
5. Saibene AM, et al. Treatment for parotid abscess: a systematic review. *Acta Otorhinolaryngol Ital.* 2022;42:106-15.
6. Akin V, et al. Septic Arthritis of the Temporomandibular Joint in a Geriatric Patient: A Case Report. *Cureus.* 2024;16(11):e73026.
7. Chaubey P, et al. *Kocuria kristinae* - An unusual opportunistic pathogen in head and neck malignancy: Case series from central India's regional cancer care centre. *Indian J Pathol Microbiol.* 2023;66:14-8.
8. Amina W, et al. *Kocuria kristinae* meningitis and cranial nerve palsies secondary to sphenoid sinusitis: about a case. *Am J Pediatr.* 2021;7:159-62.
9. Tsai CY, et al. *Kocuria varians* infection associated with brain abscess: a case report. *BMC Infect Dis.* 2010;10:102.
10. Napolitani M, et al. *Kocuria kristinae*: an emerging pathogen in medical practice. *J Med Microbiol.* 2019;68(11):1596-603.
11. Ziogou A, et al. *Kocuria* Species Infections in Humans-A Narrative Review. *Microorganisms.* 2023;11:2362.
12. The European Committee on Antimicrobial Susceptibility Testing. Breakpoint tables for interpretation of MICs and zone diameters. Version 14.0, 2024. <http://www.eucast.org>.